

The Variety of Cardiovascular Presentations of COVID-19

Fred et al.

Circulation 2020

10.1161/CIRCULATIONAHA.120.047164

The global pandemic caused by Coronavirus Disease 2019 (COVID-19) has affected more than 880,000 people in over 180 countries or regions worldwide. COVID-19 is the clinical manifestation of infection with Severe Acute Respiratory Syndrome Coronavirus-2 (SARS-CoV-2) and most frequently presents with respiratory symptoms that can progress to pneumonia and, in severe cases, acute respiratory distress syndrome (ARDS) and shock. However, there is increasing awareness of the cardiovascular manifestations of COVID-19 disease and the adverse impact that cardiovascular involvement has on prognosis. Discriminating between a cardiac or respiratory etiology of symptoms can be challenging since each may present predominantly with dyspnea. It is also critical to recognize when cardiac and pulmonary involvement coexist. In this paper, we present four cases that illustrate a variety of cardiovascular presentations of COVID-19 infection. In addition to discussing the basic clinical physiology, we also discuss clinical decision making in the current environment, while considering resource allocation and the welfare of health care professionals.

Case 1: Chest pain and ST elevation

A 64 year-old woman with a history of hypertension and hyperlipidemia and no known exposure to SARS-CoV-2 presented with persistent chest pressure for two days. She denied dyspnea, cough, fever, chills, diarrhea, recent travel or sick contacts. On admission, she was afebrile (37.1° C), blood pressure was 130/80 mmHg, heart rate 98 bpm, oxygen saturation 100% on 2 liters of oxygen. The initial electrocardiogram (ECG) showed sinus tachycardia at 102 bpm, low voltage QRS complexes in the limb leads, ST segment elevations in leads I, II, aVL, V2-V6 and PR elevation and ST depressions in aVR (Figure 1A). Troponin I on admission was 7.9 ng/mL. She was brought to the cardiac catheterization laboratory where angiography demonstrated nonobstructive coronary artery disease (Figure 1B). During the procedure the patient's blood pressure fell to 72/43 mmHg. Right heart catheterization was performed revealing a right atrial pressure of 10 mmHg, pulmonary artery pressure of 30/20 mmHg, pulmonary capillary wedge pressure of 21 mmHg and a Fick cardiac index of 1.0 L/min/m², confirming the diagnosis of cardiogenic shock. An intraaortic balloon pump (IABP) was inserted and dobutamine infusion was started with rapid normalization of blood pressure. Chest radiography demonstrated normal heart size and clear lungs (Figure 1C). Transthoracic echocardiography (TTE) demonstrated a small left ventricle with an end-diastolic dimension [LVEDD] of 2.9 cm, severe concentric left ventricular hypertrophy, left ventricular ejection fraction (LVEF) of 30%, with a dilated, severely hypokinetic right ventricle. No significant valve lesions or dysfunction were noted. A small circumferential pericardial effusion was noted (Figure 1D). Laboratory analysis revealed an arterial lactate of 5, ferritin of 967 mcg/L, C-reactive protein (CRP) of 54 ng/mL, D-Dimer 166 ng/mL (normal), There was also a small increase in M protein on serum electrophoresis, and the ratio of kappa to lambda free light chains was 2.15. The differential diagnosis included myopericarditis and cardiac amyloidosis. SARS-CoV-2 testing was positive. She was started on oral hydroxychloroquine 600 mg every 12 hours for 1 day followed by 400 mg daily for 4 additional days. On IABP and dobutamine infusion, her cardiac index and lactate normalized and her end-organ function remained stable. The troponin-I peaked at 18.6 ng/mL and subsequently trended down to 0.4 ng/mL. The IABP was weaned after 7 days and the patient remained hemodynamically stable off IABP and inotropes. On repeat echocardiography on hospital day 10, LVEF improved to 50% and wall thickness was reduced.

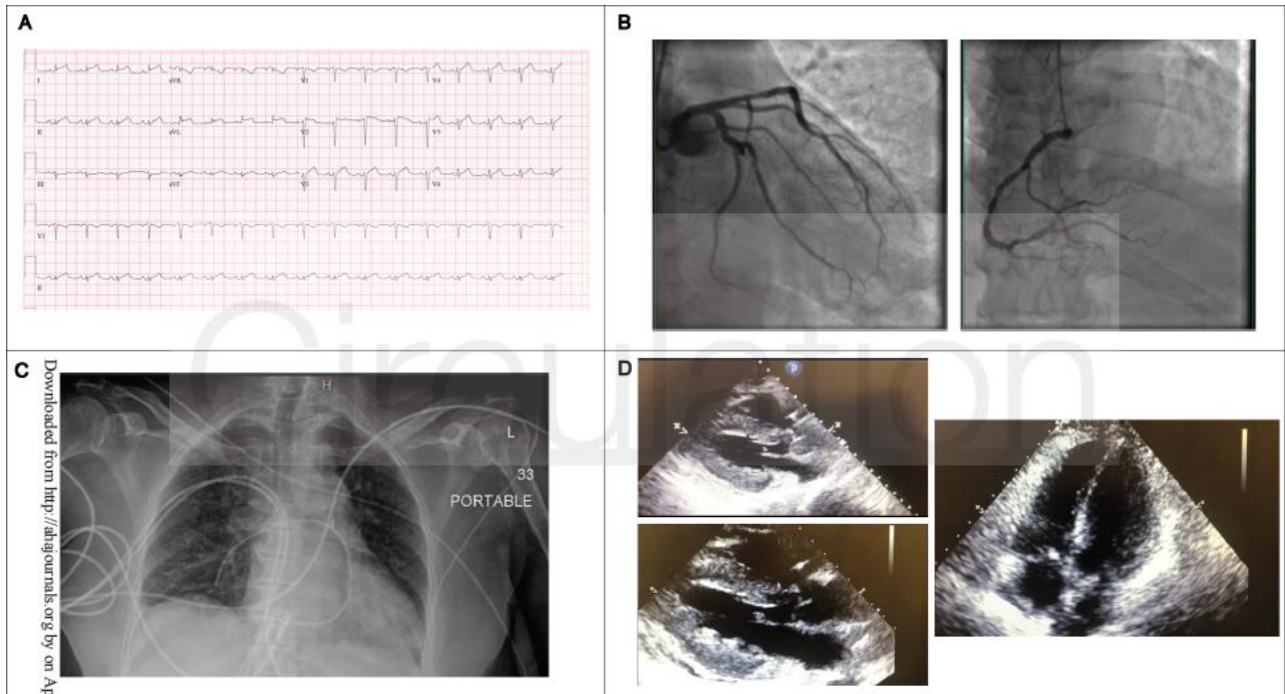


Figure 1. Chest Pain and ST-elevation. Initial electrocardiogram showed sinus tachycardia, low voltage QRS complexes in the limb leads and diffuse ST elevation in leads I, II, aVL and leads V2-V6 (Panel A); Coronary angiogram demonstrated mild disease in the left anterior descending artery and left circumflex artery and 40% stenosis in the mid right coronary artery (Panel B); Chest radiography demonstrated clear lungs (Panel C); Transthoracic echocardiogram with severe increased left ventricular wall thickness and left ventricular ejection fraction approximately 30% with trace circumferential pericardial effusion (Panel D).

Discussion

The predominant presenting symptoms of this patient were cardiac in nature without symptoms suggestive of infection. Thus, although the initial ECG findings of diffuse ST elevations and elevated cardiac enzymes raised the possibility of myopericarditis, the typical diagnostic algorithm for acute coronary syndrome was followed, since this remains a more common cause of this presentation. As experience with the COVID-19 pandemic grows, the treatment pathway for cardiac presentations may also evolve rapidly. One area of uncertainty is whether to proceed to coronary angiography in response to ECG changes and positive troponin, which risks exposing additional health care personnel to infection.³ Likewise, the role of endomyocardial biopsy to detect myocarditis is uncertain. In this case, hemodynamic assessment played a crucial role in the detection of profound cardiogenic shock, guiding appropriate management to achieve a successful outcome. To reduce the potential contamination associated with patient transport to the catheterization suite, bedside placement of a pulmonary artery catheter and IABP may be considered when coronary angiography is not required. Other potential indicators of the hemodynamic status may include sampling the central venous saturation or hemodynamic assessment via echocardiography. Whether the increased wall thickness present in this patient will be characteristic of myocarditis-like presentations with COVID-19 will need further study. A low threshold to assess for shock in acute systolic HF associated with COVID is important. Likewise, there should be a low threshold for SARS-CoV-2 testing in patients presenting with signs of myopericarditis even in the absence of fever and respiratory symptoms. Although the patient in this case improved in the short term, the long-term effects of the myocardial injury are still to be determined.

Case 2: Cardiogenic shock rescued by VAV ECMO

A 38 year-old man with a history of type 2 diabetes mellitus presented with one week of cough, pleuritic chest pain and progressive shortness of breath to an outside hospital. On presentation, he was tachypneic with an oxygen saturation of 93% on room air. Initial labs were notable for a white blood cell (WBC) count of 9,000 per microliter with 11% band forms, 11% lymphocytes, a venous lactate of 1.7 mmol/L, and normal renal and liver function. The chest radiograph showed bilateral pulmonary opacities. Testing for SARS-CoV-2 was positive. Over the course of the next 6 hours, his respiratory status rapidly deteriorated, requiring intubation for hypoxemic respiratory failure. TTE demonstrated normal left ventricular function. He developed a supraventricular tachycardia (SVT) with a rate greater than 200 bpm and was successfully cardioverted. Despite deep sedation and paralysis, the arterial blood gas revealed pH 7.26, pCO₂ 40 mmHg,

and pO₂ 56 mmHg on 100% fraction of inspired oxygen and positive end-expiratory pressure of 16 mmHg. Our mobile extracorporeal membrane oxygenation (ECMO) team was rapidly dispatched. Prior to ECMO cannulation, the patient had a bradycardic arrest lasting six minutes. He was cannulated for venovenous (VV) ECMO with a left femoral 25F drainage cannula and left internal jugular 20F reinfusion cannula. Following initiation of VV ECMO, his oxygenation was acceptable but he became hypotensive requiring vasopressors. Upon arrival at our institution, the blood pressure was 85/70 mmHg and laboratory analysis showed an arterial lactate of 5.1 mmol/L, CRP >300 mg/L, ferritin 4420 ng/mL and interleukin-6 of 331.8 pg/mL. The chest radiograph showed diffuse ill-defined airspace opacities bilaterally (Figure 2A). He was started on hydroxychloroquine (same dosing protocol as Case 1).

Over the next 12 hours, the patient had a persistently elevated lactate, ongoing pressor requirement and declining urine output. The ECG showed low limb lead voltage, sinus tachycardia and he was noted to have runs of an accelerated idioventricular rhythm (Figure 2B). TTE showed LVEDD of 4.5 cm, LVEF 20-25%, with akinesis of the mid left ventricular segments, and normal right ventricular size with mildly reduced function (Figure 2C). High sensitivity troponin T was 1341 ng/L. After a multidisciplinary discussion, a 15F arterial limb was added via the right femoral artery to convert the circuit to veno-arterial-venous (VAV) ECMO, achieving 2L of arterial flow. Systemic heparin was maintained with a goal activated partial thromboplastin time of 45-60 seconds. Over the next 24 hours, the pressor requirement decreased and the lactate normalized. The patient was decannulated from ECMO after 7 days and is hemodynamically stable, although he remains on mechanical ventilation.

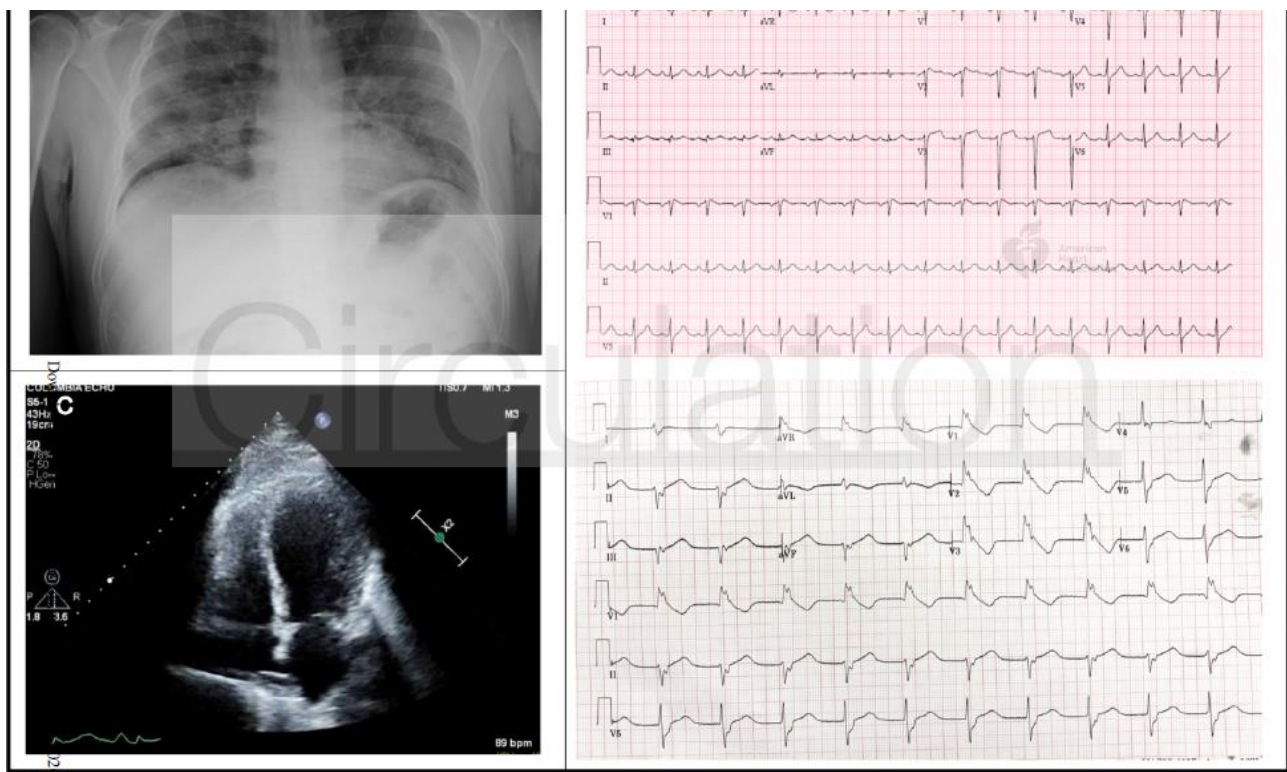


Figure 2. Cardiogenic shock rescued by VAV ECMO. Chest radiograph showed diffuse illdefined airspace opacities bilaterally (Panel A); Initial electrocardiogram (Top) demonstrated sinus tachycardia with incomplete right bundle branch block; Repeat electrocardiogram (Bottom) demonstrated accelerated idioventricular rhythm (Panel B); Transthoracic echocardiogram demonstrated left ventricular end-diastolic diameter of 4.5 cm, left ventricular ejection fraction 20-25%, with akinesis of mid left ventricular segments (Panel C).

Discussion

The initial presentation of this case was more characteristic of severe COVID-19 disease than case 1 above. Acute respiratory distress syndrome (ARDS) with profound hypoxia necessitated treatment with VV ECMO. The cardiac involvement only became evident after the initiation of VV ECMO. The etiology of cardiac dysfunction in this case may be multifactorial. Direct cardiac injury may occur as the result of viral invasion, while the cytokine storm induced by COVID-19 may also have toxic effects on the myocardium. In this case, myocardial stunning following the cardiac arrest or stress cardiomyopathy are other potential explanations for the severe left ventricular dysfunction. This case highlights the need for a multidisciplinary approach to these patients with frequent reassessment of response to mechanical circulatory support. Reports of ECMO

use in COVID-19 patients are limited, and the outcomes are unknown. Even if ECMO shows clinical utility, it will play a limited role overall in the current pandemic, due to the extensive resources required to provide the therapy and limited availability. In this case, 2 L/min of blood flow support was sufficient to maintain hemodynamic stability until the inflammatory response subsided. It will be of interest to see if such relatively low levels of hemodynamic support are sufficient in other cases with COVID-19 related cardiogenic shock. A benefit of supporting patients with relatively low arterial flow rates is a decreased likelihood of LV distention with its associated consequences.

Case 3: Decompensated heart failure

A 64 year-old woman with a non-ischemic cardiomyopathy (recent normalization of LVEF), atrial fibrillation, hypertension and diabetes presented with a non-productive cough and shortness of breath for two days. On arrival, she was afebrile, with blood pressure 153/120 mmHg, heart rate 100 bpm, and oxygen saturation 88%. Chest radiography revealed bibasilar predominant patchy airspace opacities, pulmonary vascular congestion and small bilateral pleural effusions (Figure 3A). ECG showed sinus rhythm, an isolated premature ventricular complex, premature atrial complexes, lateral T wave inversions and QTc 528 ms (Figure 3B). Laboratory analysis revealed WBC 6,100 per microliter, serum creatinine 1.11 mg/dL, aspartate aminotransferase 527 U/L, alanine aminotransferase 232 U/L, N-terminal pro B-type natriuretic peptide 6,137 pg/mL, high-sensitivity Troponin T 42 ng/mL, CRP 19.4 mg/L, ferritin 639 ng/mL and interleukin-6 12 pg/mL. Testing for SARS-CoV-2 was positive. She was started on broad spectrum antibiotics, including intravenous azithromycin, for management of pneumonia, but hydroxychloroquine was withheld due to the prolonged QT. Her heart failure was treated with intravenous furosemide and intravenous nitroglycerine. Her respiratory status worsened rapidly, requiring intubation. She developed hypotension and was started on vasopressors. An arterial lactate was 6.7 mmol/L. A bedside TTE showed severely reduced left ventricular (LV) function. She was ventilated with a low tidal volume strategy. Bedside pulmonary artery catheterization revealed a right atrial pressure of 10 mmHg, pulmonary artery pressure 45/20 mmHg, with a Fick cardiac index of 1.7 L/min/m². Dobutamine was started but was discontinued when she developed polymorphic ventricular tachycardia requiring cardioversion (Figure 3C). IABP was considered but deferred due to improvement in the arterial lactate and blood pressure. Troponin levels remained relatively stable throughout (peak 214 ng/mL). She remains intubated on day 9 of her hospitalization due to agitation with ventilator weaning attempts.

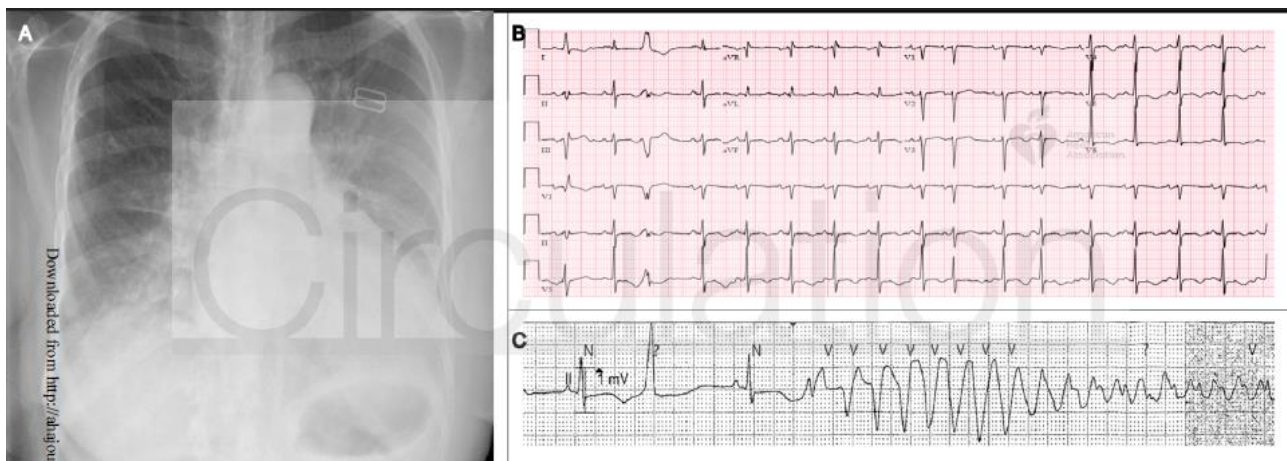


Figure 3. Decompensated Heart Failure. Chest radiography shows pulmonary vascular congestion, patchy airspace opacities at bases and bilateral pleural effusions (Panel A); Electrocardiogram shows sinus rhythm with premature atrial and ventricular complexes, lateral T-wave inversions and a prolonged QT interval (Panel B). Telemetry strip shows prolonged QT interval and Torsades de Pointes following R-on-T phenomenon (Panel C).

Discussion

In this case, a patient with underlying cardiac disease developed profound decompensation in the context of COVID-19 infection, characterized by a recurrence of a reduced LVEF accompanied by cardiogenic shock and proclivity for tachyarrhythmias. Neither myocarditis nor cytokine storm were probable mediators of the recurrence of her depressed cardiac function, given the relatively low biomarker levels. Whether patients with recovered systolic function will be at similar risk for this recrudescence of reduced LVEF awaits further study. Due to tachyarrhythmias, management of the cardiogenic component of her shock with inotropic agents was not feasible. However, early intubation and reversal of her respiratory failure led to improvements in hemodynamics in the absence of direct cardiac support. This case also highlights the need

for rapid correction of hypoxemia in patients with an underlying heart failure, and the usefulness of pulmonary artery catheterization when shock is thought to be multifactorial. In patients with a co-existing cardiomyopathy, baseline QT prolongation may impact consideration of use of hydroxychloroquine and azithromycin.

Case 4: Heart transplant recipient

A 51 year-old man with a history of heart transplantation in 2007 and renal transplantation in 2010 presented with intermittent fever, dry cough, and shortness of breath for nine days. He denied any recent travel or sick contacts. His outpatient immunosuppression included tacrolimus 5 mg twice daily, mycophenolate mofetil 250 mg twice daily, and prednisone 5 mg daily. He was afebrile with a heart rate of 84 bpm, blood pressure of 137/84 mmHg and oxygen saturation of 97% on room air. His chest radiograph was notable for multifocal bilateral patchy airspace opacities (Figure 4A). The ECG demonstrated normal sinus rhythm with new nonspecific T-wave inversions in the inferior and lateral leads (Figure 4B). Laboratory analysis revealed WBC 2,750 per microliter with lymphopenia and a serum creatinine 4.3 mg/dL. Other notable labs included ferritin 1514 ng/mL, CRP 129.27 mg/L, interleukin-6 120 pg/mL, D-dimer 1.03 ug/mL, N-terminal proB-type natriuretic peptide 3212 pg/mL and high-sensitivity troponin T 16 ng/L. Testing for SARS-COV-2 was positive. Following admission, the mycophenolate mofetil was discontinued. The patient was started on hydroxychloroquine (same dose as previous cases) and azithromycin 500 mg daily for treatment of COVID-19. He was also started on ceftriaxone for empiric treatment of pneumonia. TTE showed normal cardiac allograft function. Through the first five days of the hospitalization, the patient was intermittently febrile and his inflammatory markers remained persistently elevated, though he remained clinically stable. He was discharged home after 7 days in the hospital.

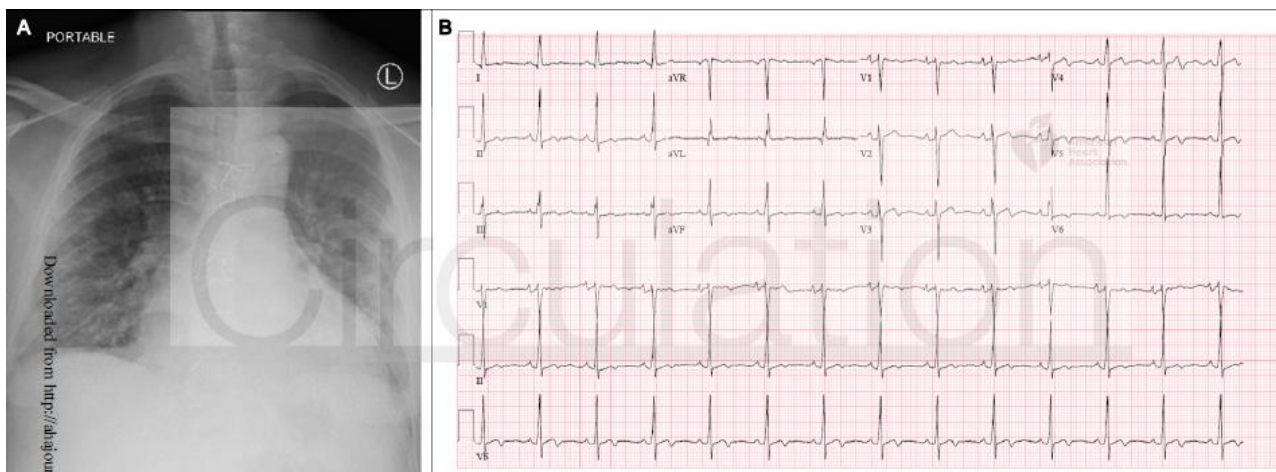


Figure 4. Heart transplant recipient. Chest radiography with multifocal bilateral patchy airspace opacities (Panel A); Electrocardiogram with normal sinus rhythm with new nonspecific ST changes and T wave inversions in inferior and lateral leads (Panel B).

Discussion

The COVID-19 pandemic presents a unique challenge for solid organ transplant recipients. The clinical symptoms of the patient described in this case were similar to what has been described in non-immunosuppressed patients with COVID-19. Of note, the patient in this case was more than two years post-transplant. At this point, immunosuppression levels are generally much lower than those used in the first months following a transplant. Data are limited about how to adjust immunosuppression during COVID-19 infection. In this case, we stopped the mycophenolate mofetil during the infection, with a plan to resume it following full recovery. In addition to considerations for transplant recipients, the COVID-19 pandemic has had an additional impact on how heart transplant programs manage their patients on the waitlist. Programs must balance the risks of new transplant recipients contracting COVID-19 during their hospitalization with the risks of waitlist mortality if transplantation is postponed. Furthermore, COVID-19 may also impact the donor pool due to diversion of crucial resources and fear of disease transmission from donors.

Take-home Message

The cases above illustrate the variable presentation of COVID-19 involvement of the cardiovascular system and highlight evolving considerations for treatment pathways across the spectrum of patients with preexisting cardiovascular diseases (Fig. 5). In patients presenting with what appears to be a typical cardiac

syndrome, COVID-19 infection should be in the differential during the current pandemic, even in the absence of fever or cough. One should have a low threshold to assess for cardiogenic shock in the setting of acute systolic heart failure related to COVID. If inotropic support fails in these patients, we consider IABP as the first line mechanical circulatory support device because it requires the least maintenance from medical support staff. When patients on VV ECMO for respiratory support develop superimposed cardiogenic shock, the addition of an arterial conduit at relatively low blood flow rates may provide the necessary circulatory support without inducing LV distension. Our experience confirms that rescue of patients even with profound cardiogenic or mixed shock may be possible with temporary hemodynamic support at centers with availability of such devices. COVID-19 infection can cause decompensation of underlying heart failure, and may lead to mixed shock. Invasive hemodynamic monitoring, if feasible, may be helpful to manage the cardiac component of shock in such cases. Medications that prolong the QT interval are being considered for COVID-19 patients and may require closer monitoring in patients with underlying structural heart disease. Our heart transplant recipient exhibited similar symptoms of COVID-19 infection as compared to the general population. For those transplant patients requiring hospitalization, how to alter the anti-metabolite and immunosuppression regimens remains uncertain. Furthermore, the COVID-19 pandemic creates a challenge for the management of heart failure patients on the heart transplant waitlist, forcing physicians to balance the risks of delaying transplant with the risks of donor infection and uncertainty regarding the impact of post-transplant immunosuppression protocols.

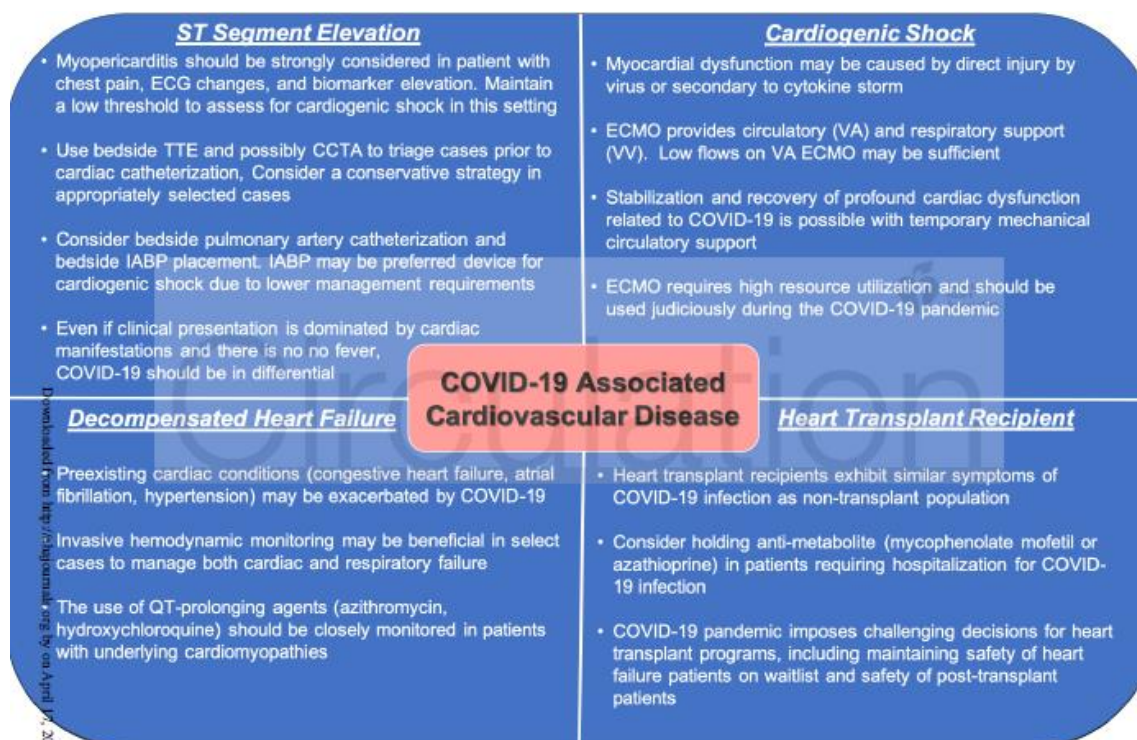


Figure 5. Important messages from each cardiovascular presentation of COVID-19
 CCTA=Cardiac computed tomographic angiography, COVID-19=corona virus disease 2019, ECMO=Extracorporeal membrane oxygenation, ECG=Electrocardiogram, IAB=Intraaortic balloon pump, TTE=transthoracic echocardiogram, VA=Veno-arterial, VV=Veno-venous